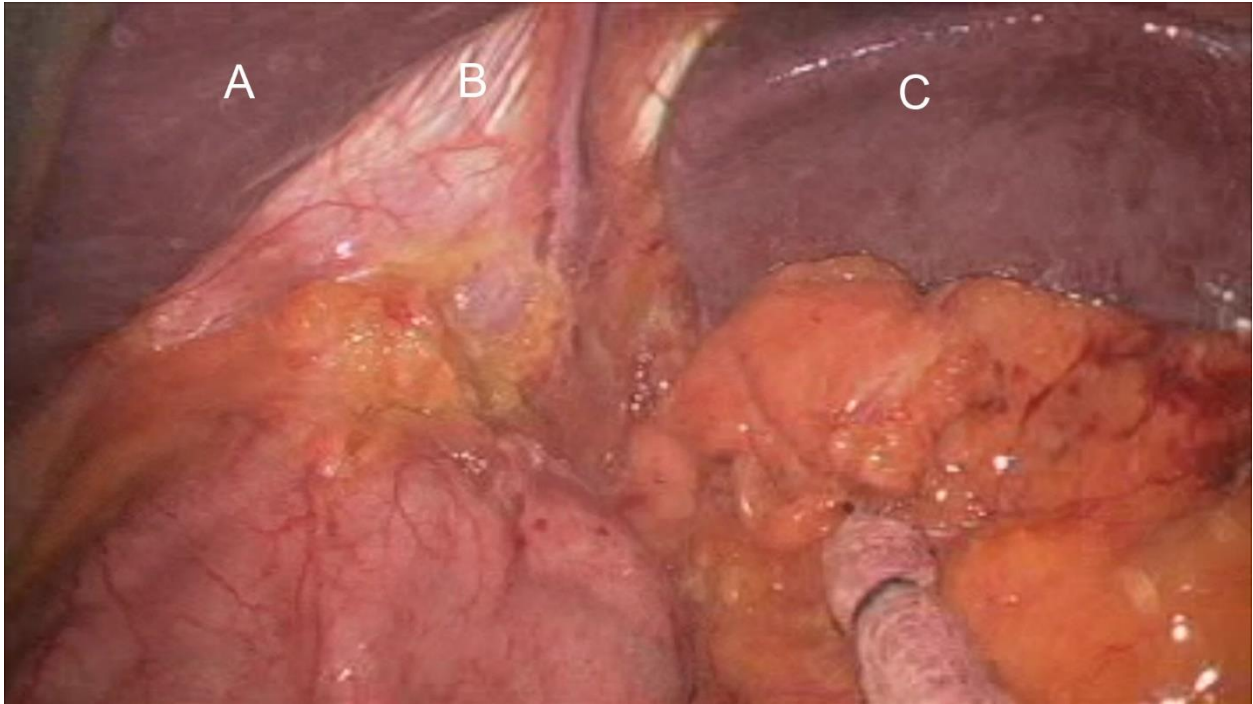


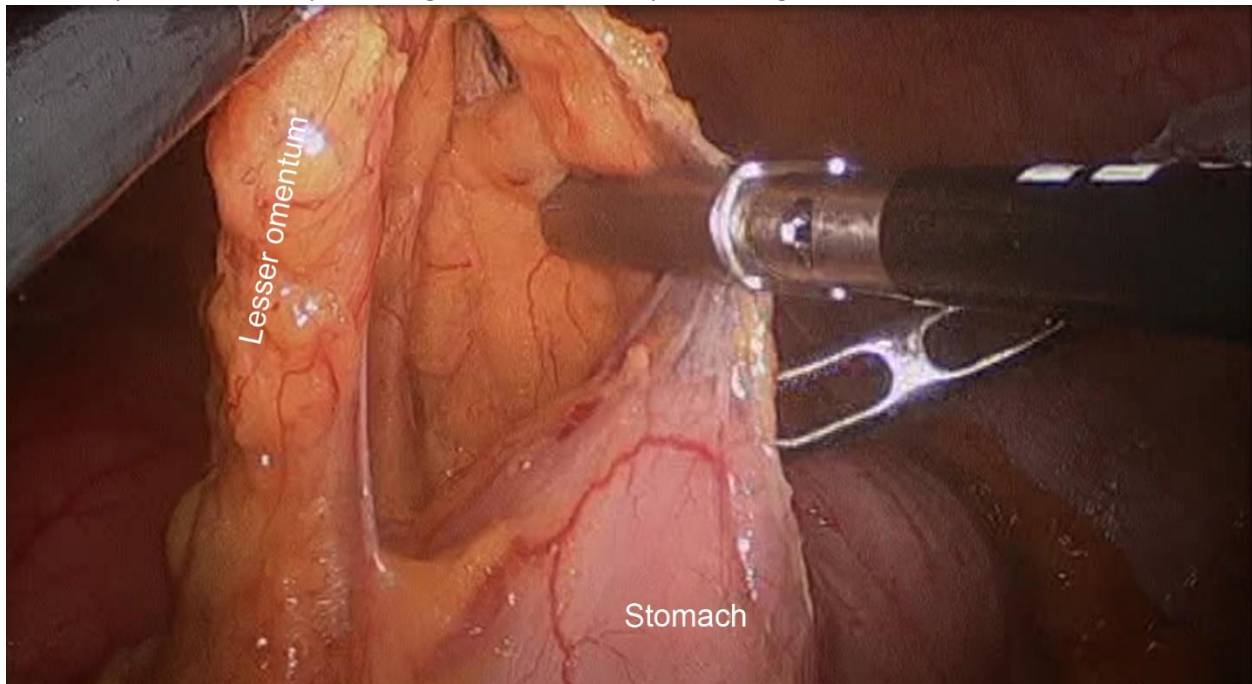
Laparoscopic Anatomy Videos Pre/Posttest Comprehension Questions

1. Identify the following pictured structures:

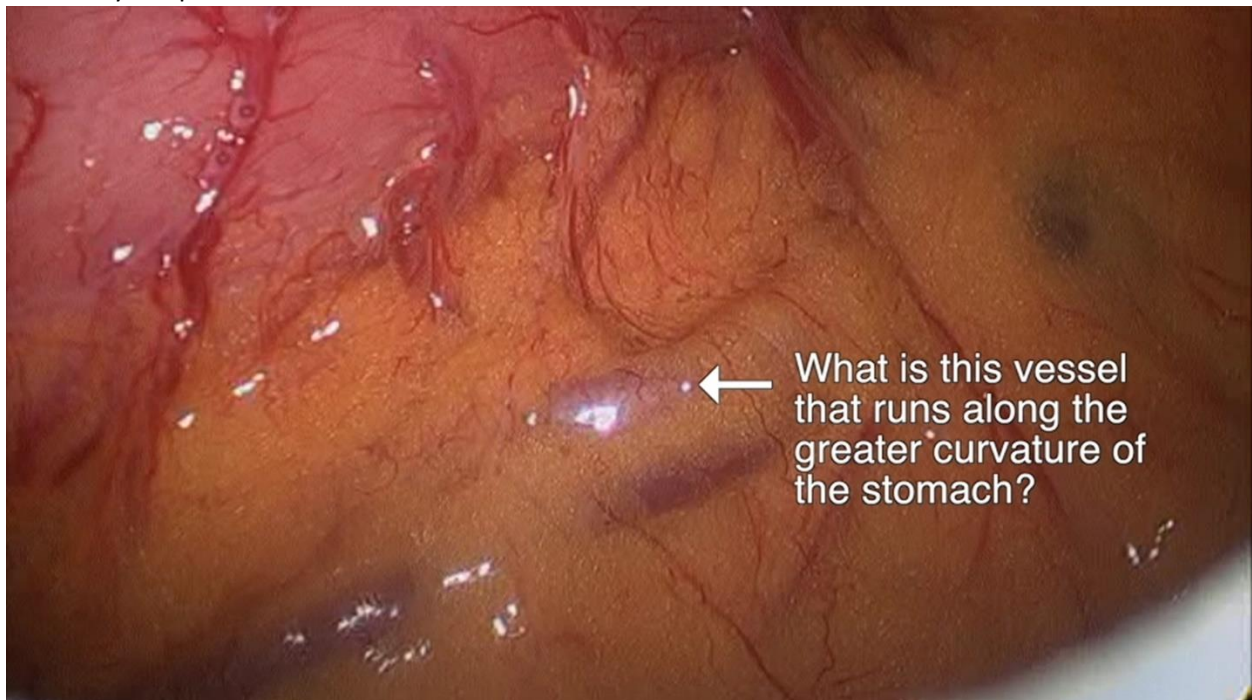- a)
- b)
- c)



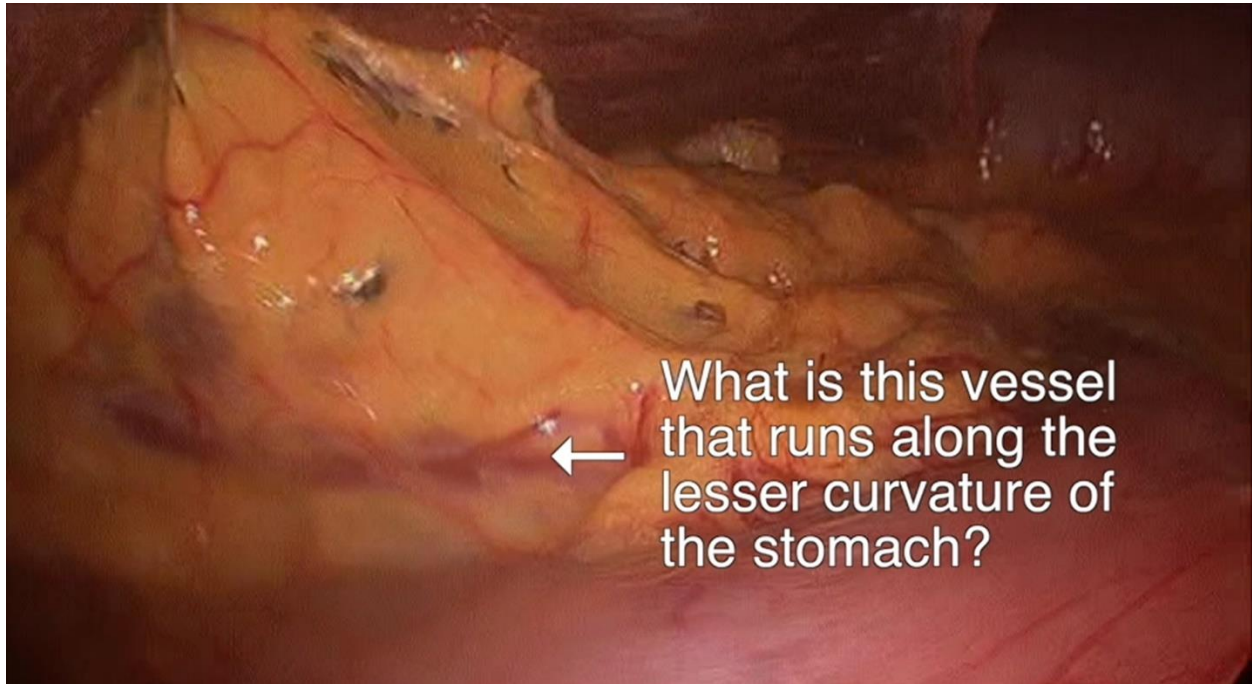
2. Identify the anatomic space being entered in the depicted image:



3. Identify the pictured vessel:



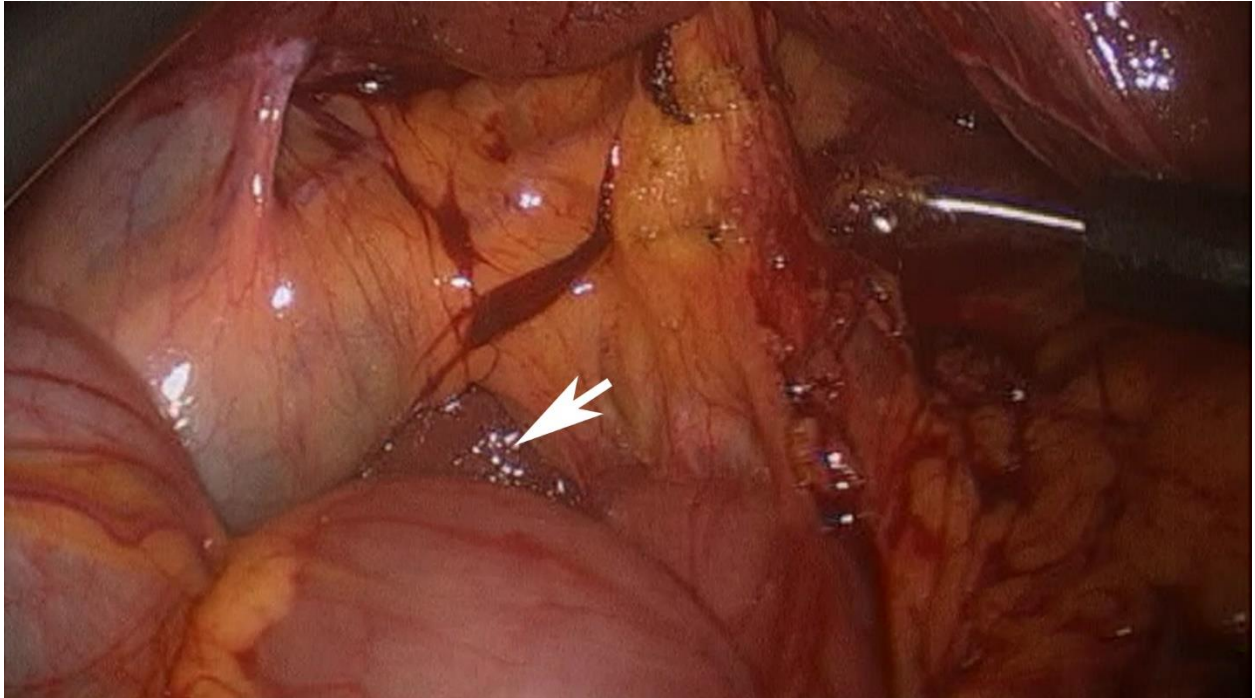
4. Identify the pictured vessel:



5. Identify three organs or structures that border the lesser sac

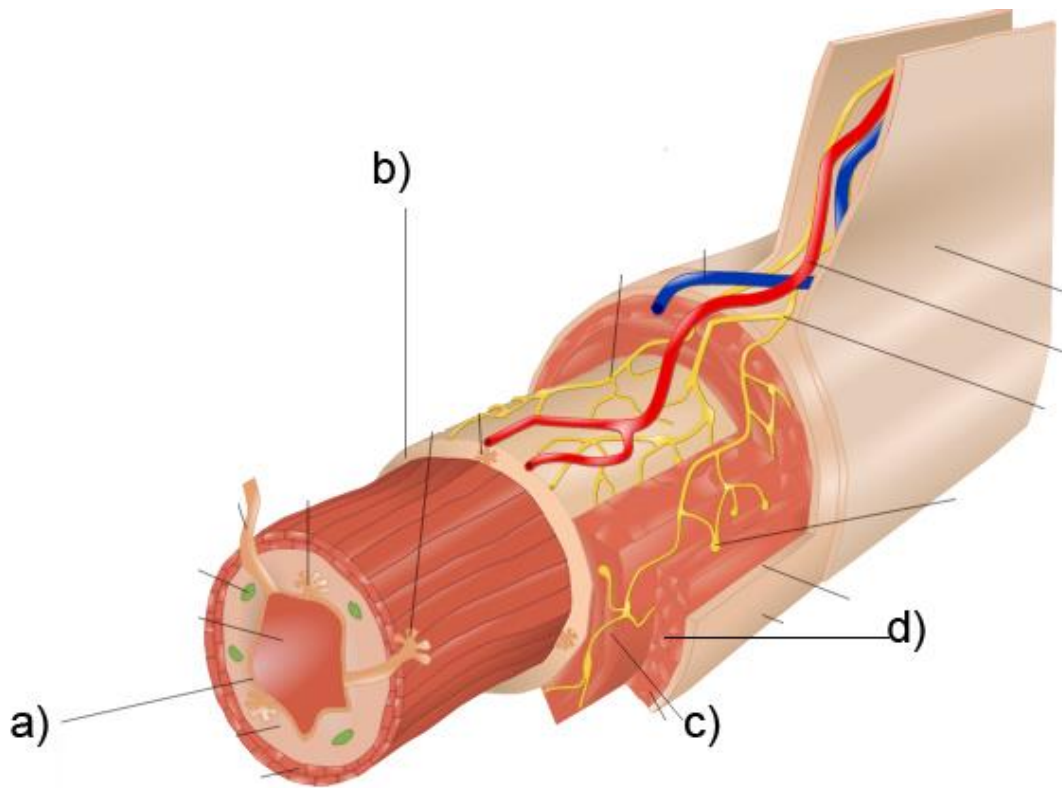
- a)
- b)
- c)

6. Identify the pictured anatomic space that allows for entrance into the lesser sac:



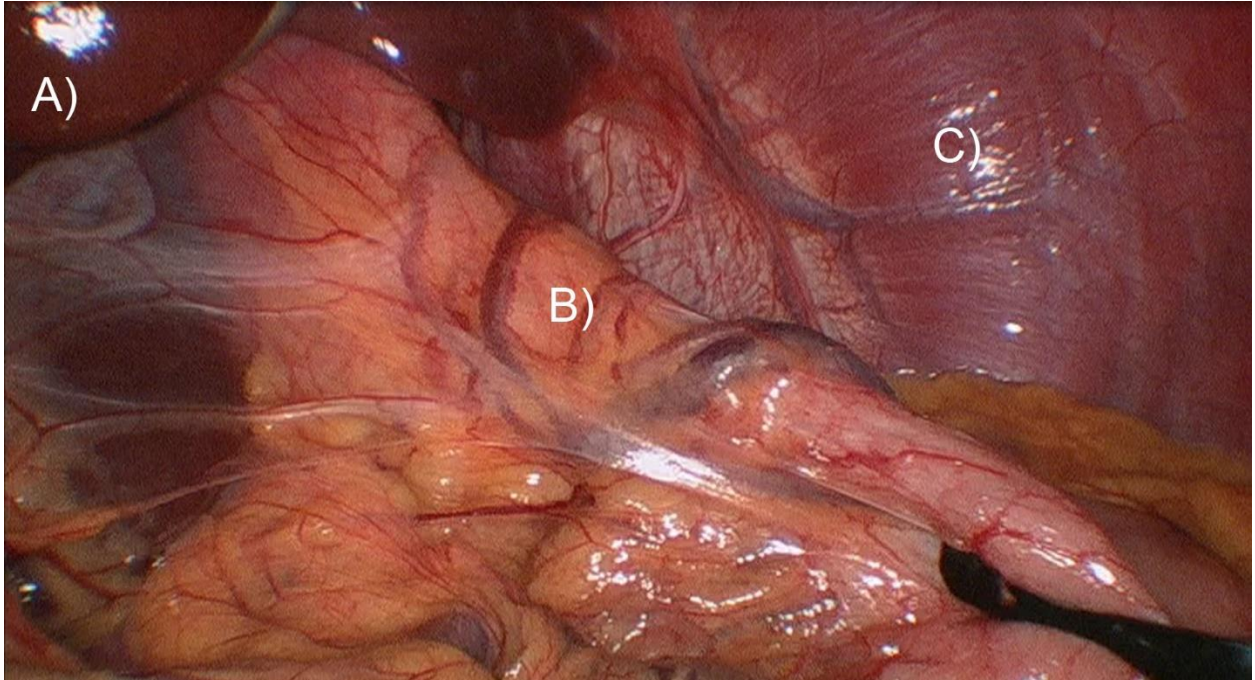
7. Identify the following layers of the GI tract:

- a)
- b)
- c)
- d)

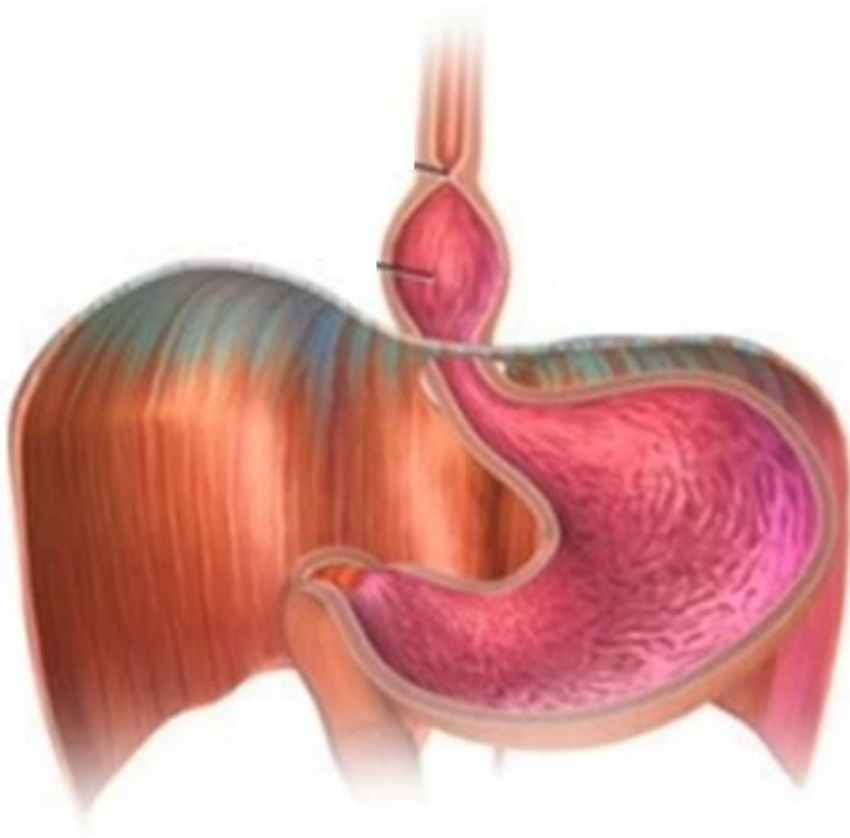


8. Identify the following pictured structures (camera is pointed cephalad)

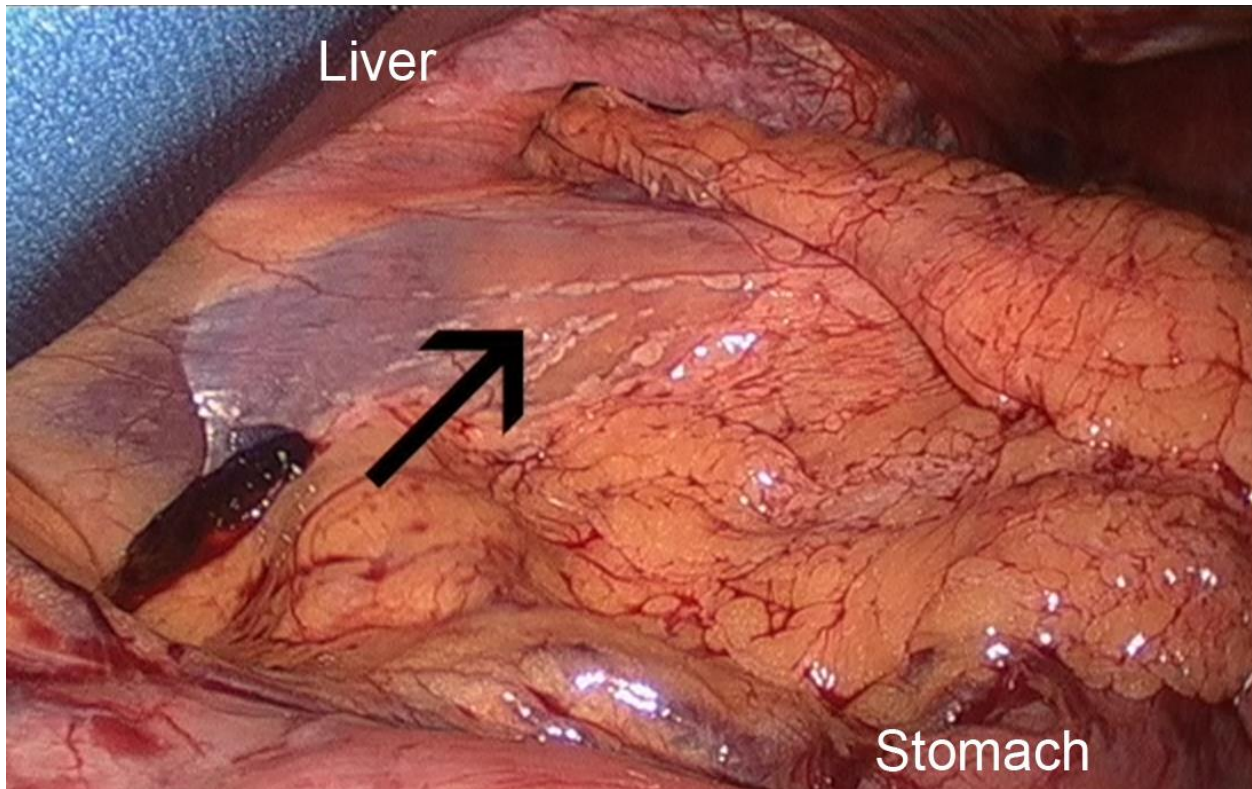
- a)
- b)
- c)



9. What is the name of the pictured condition?



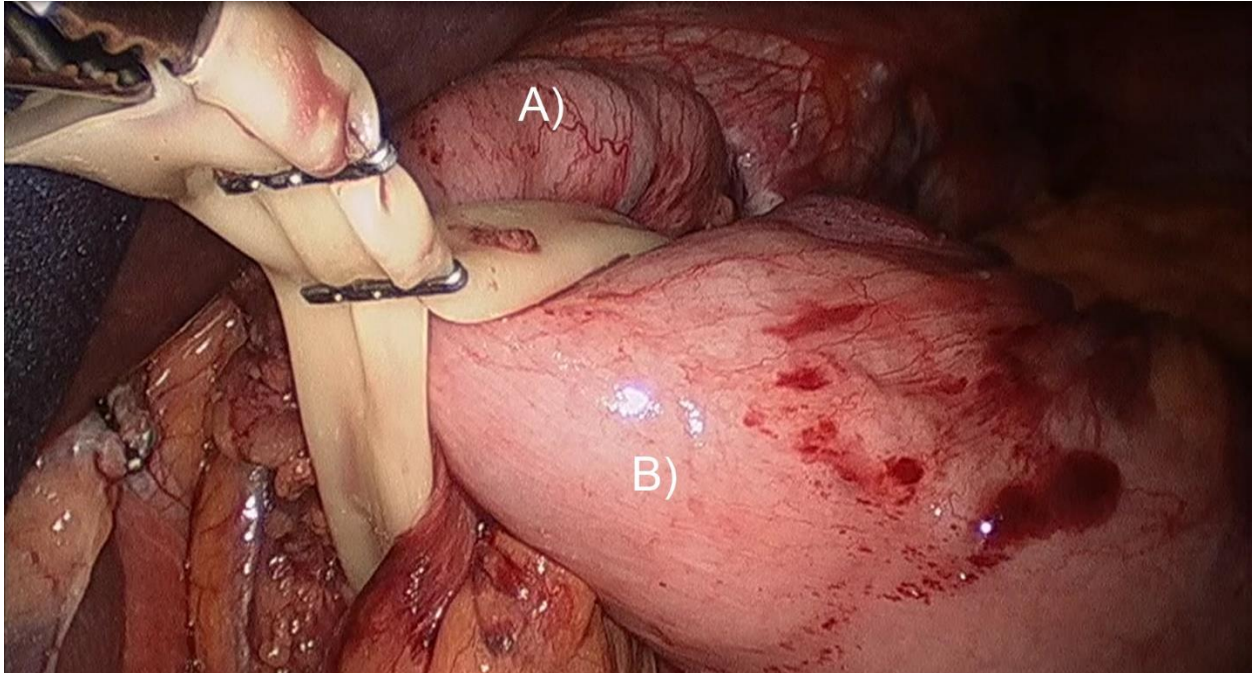
10. What is the name of the depicted connective structure?



11. Identify the following pictured structures

a)

b)



12. What is the name of this large vessel (A) running parallel to the esophagus?

a)

